

CHARACTERIZATION OF ALVEOLAR SOFT PART SARCOMA OF THE TONGUE: A CLINICO-PATHOLOGIC STUDY AND SCOPING REVIEW

A.O. Akinyamoju¹; O.O. Gbolahan²; and B.F. Adeyemi¹

1. Department of Oral Pathology, Faculty of Dentistry, College of Medicine, University of Ibadan/University College Hospital Ibadan, Nigeria.
2. Department of Oral and Maxillofacial Surgery, Faculty of Dentistry, College of Medicine, University of Ibadan/University College Hospital Ibadan, Nigeria.

Correspondence:

Dr. A.O. Akinyamoju

Department of Oral Pathology,
Faculty of Dentistry,
College of Medicine,
University of Ibadan/
University College Hospital,
Ibadan, Nigeria.
E-mail: akindayo2002@yahoo.com

ABSTRACT

Background: Alveolar soft part sarcoma (ASPS) is a rare malignant soft tissue tumour. There is a dearth of literature analyzing its features on the tongue.

Objectives: This study aims to conduct a scoping review to describe the essential clinico-pathologic features, treatment modalities and outcome of previously reported tongue ASPS (TASPS) and new cases at our center.

Methods: A search of databases (PubMed, Medline, Cochrane and Google Scholar) and the internet for articles on TASPS written in English was conducted. Information extracted included clinico-pathological and demographic data. Descriptive statistics was used for analysis.

Results: A total of 49 articles were eligible for this study. In all, 81 cases were utilized. Asian studies accounted for most cases 35(43.2%) and a slight female preponderance of 1.1 was seen. Most cases - 38 (46.9%), occurred in the 1st decade and the base of tongue was the most common location in 19 (39.6%) cases. Also, tumour metastasis was present in 14 (25.9%) cases. Transcription Factor E3 (TFE3) – 8 (24.2%) and Neuron Specific Enolase (NSE) – 8 (24.2%) were the most common immunohistochemical stains used and were both expressed 7 out of 8 cases (87.5%). Most common treatment modality was surgery and 42 (82.4%) cases managed by surgery alone were free of disease at ≤ 5 years of follow up.

Conclusions: TASPS slightly affected the female gender and tongue base more commonly. It occurred more in the first two decades of life. Use of standard investigative tools for management will allow for better appraisal of research findings.

Keywords: Tongue; Alveolar; Soft-part; Sarcoma; Treatment outcome

INTRODUCTION

Alveolar soft part sarcoma (ASPS) is a rare malignant soft tissue tumour that accounts for about 1% of all soft tissue sarcomas.^{1,2} It was first described in 1952 by Christopherson and Stewart.³ Despite numerous studies since then, the histiogenesis, biologic behavior and best treatment modality has remained debatable. The head and neck region is the favored site for ASPS in children and adolescents while the thigh and buttocks are common sites for ASPS in adults.⁴⁻⁶ Also, a female predilection has been reported in cases occurring in the 1st and 2nd decades of life while a slight male preference was observed after the 3rd decade.⁷⁻⁹

Presentation of ASPS is usually that of a slow growing painless mass, with a high rate of metastasis to the lungs, bone, and the brain, which could occur long after excision of the primary tumour.^{2,7,10} ASPS could present clinically as a vascular lesion and magnetic

resonance imaging (MRI) of the tumour with contrast enhancement is ideal to demonstrate its vascular nature¹¹⁻¹³ whilst differentiating it from other vascularized tumours.

Microscopically, ASPS consists of large polygonal to round cells with distinctive cell membrane, abundant eosinophilic granular cytoplasm, round to oval eccentric nuclei with prominent nucleoli which may be multiple. Neoplastic cells are characteristically disposed in nested or organoid growth pattern separated by thin fibrous septa.^{6,14,15} The cells may appear non-cohesive, giving it the alveolar pattern. Those without organoid patterns have also been described as well as those with clear cytoplasm. The solid pattern is more frequently seen in pediatric cases.¹⁶ The tumour is well vascularized by delicate sinusoidal vascular channels lined by a single layer of endothelial

cells. Pleomorphism and mitosis are infrequent. About 80% of ASPS have intracytoplasmic, periodic acid–schiff positive, diastase-resistant rhomboid- or rod-shaped crystals.¹⁶

Furthermore, ASPS have been reported to commonly occur on the tongue in many studies, as well as in case reports and constitute 25% of all ASPS.¹⁷⁻²¹ Also, tongue alveolar soft part sarcoma (TASPS) occurs in patients much younger than those for ASPS from other anatomical locations particularly in females.^{2, 18, 22, 23}

There are many reports describing the clinico-pathologic features of ASPS.^{10, 18, 24} However, there is a dearth of literature analyzing these features in tongue tumours only, despite the tongue being a common site of presentation in the head and neck region. Therefore, it is desirable to assess the characteristics of TASPS and to assess the available treatment modalities necessary to achieve a desirable outcome in the management of this entity. This study aims to describe the essential clinico-pathologic features, treatment modalities and outcome of previously reported TASPS by conducting a scoping review along with present cases seen at the Oral Pathology Department, University College Hospital, Ibadan.

MATERIALS AND METHODS

Study design

This study was a review of previous studies describing the clinico-pathologic features of TASPS. A scoping review was conducted because the available studies on TASPS varied in their methods and data, thus precluding the conduct of a meaningful meta-analysis. The review was performed following the Preferred Reporting Items for Systematic Reviews and Meta-Analyses extension for Scoping Reviews (PRISMA-ScR) Checklist.²⁵

Methods

The histopathology records of the Department of Oral Pathology, University College Hospital (UCH), Ibadan over a period spanning 26 years were examined. All entries of cases diagnosed as ASPS were retrieved, while TASPS were identified for analysis. The haematoxylin and eosin (H&E) slides of these cases were retrieved and reassessed to verify the diagnosis. Case files of eligible cases were retrieved and information on bio data, duration of symptoms, symptoms on presentation, presence of tumour spread or metastasis at diagnosis, site of metastasis if present, clinical impression, treatment received, duration of follow up and status at follow up were obtained, cases with incomplete records were excluded from the study.

Literature search

To identify relevant studies, an all-inclusive search of the databases (PubMed, Medline, Cochrane and Google Scholar) as well as an internet search of articles written in English language was conducted between August and October 2019. Keywords used for the search included a blend of “alveolar soft-part sarcomas (ASPS),” “soft-tissue tumours,” and/or “tongue.” Also, relevant citations identified in the reference lists of selected articles were included in the search. The search lists from the electronic sources were merged and duplicates were removed. The title and abstract of the identified articles were screened to remove studies outside the scope of this review after which the full text of all potentially eligible articles were retrieved for further analysis. Articles that did not satisfy the inclusion criteria were excluded from further consideration. Also, a manual search of bibliographies of identified articles was done by cross referencing eligible publications on ASPS from 1957 till date while relevant citations identified in the reference lists of selected articles were included in the search to identify additional studies of interest. The selection process is displayed in a flow chart (Figure 1).

Criteria for eligibility

Articles included were human case reports/case series, letter to editors and review articles on ASPS of the tongue either in whole, or as part of a series on ASPS. Articles that were not available in English or which the full text could not be obtained were excluded from the study. Similarly, ASPS that metastasized to the tongue as well as cases with incomplete data were excluded from the study.

Extraction of data

A proforma was used to extract data from eligible articles by two investigators (AOA, BFA) independently. Information extracted included clinico-pathological and demographic data such as year of publication, country of publication, type of study, patients’ age, gender, location and surface of tongue affected, duration of symptoms, symptoms on presentation, presence of tumour metastasis at diagnosis, site of metastasis if present, clinical impression, result of immunohistochemical studies (when available), treatment type, duration of follow up and status of patients at last follow up. Any inconsistencies were resolved by consensus with a third investigator (GOO).

Statistical analysis

Descriptive statistics was used for analysis. Relevant data were extracted from the included studies and variables were presented using summary statistics and tables. Data analysis was done using SPSS software version 21 (IBM Corporation, Armonk, NY, USA).

RESULTS

Initial electronic search of the databases identified 29 potentially eligible articles. An additional 31 publications were identified from other sources (bibliography of initially identified articles). After initial review of the titles and abstracts, four duplicate articles were removed and 56 articles which met the inclusion criteria were identified. Eight of these were excluded because two were not written in English language, while full text articles were unobtainable for another six. Also, one eligible article was identified and included following a hand search. Thus, a total of 49 articles (39 case reports and 10 case series) were utilized in this study.

Furthermore, five cases of ASPS were identified from the records of Oral Pathology Department, UCH, Ibadan. Four affected the tongue, while one affected the cheek and was excluded from further analysis. The age range of cases was 6 to 34 years; while male to female ratio was 3:1. Also, the site of predilection was the dorsal surface of the anterior tongue (Figure 2). Duration of symptoms ranged from three months to four years with tumours in the anterior dorsum and sulcus terminalis areas having a shorter duration than posterior and ventral tongue tumours.

Histopathology of all cases showed tissue disposed in organoid pattern of large round to oval eosinophilic cells separated by moderately to highly vascularized fibrous connective tissue stroma. Individual cells have abundant granular cytoplasm with some having eccentric nuclei while others had vesicular nuclei, (Figure 3). The clinical data of the present cases have been summarized in Table 1.

the mean age of cases was 13.9 ± 12.2 years while the mode was 3 years and median age was 11 years. Patients' age at presentation ranged from 11 months to 64 years and most cases (38/46.9%) occurred in the 1st decade followed by the 2nd (24/29.6%) and 3rd (12/14.8%) decades and declined gradually to one case in the 7th decade (Table 3).

On the tumour location, only 48/81 (59.3%) cases reported the location of tumour on tongue. The base was involved in 19/48 (39.6%) followed by the lateral border 13/48 (27%) and anterior tongue- 8/48 (16.6%) cases. Other tongue sites were recorded as follows: posterior tongue- 2/48 (4.2%), sulcus terminalis- 2/48 (4.2%), mid-portion- 2/48 (4.2%), root- 1/48 (2.1%) and anterior to base- 1/48 (2.1%). Also, only 32/81 (39.5%) cases reported the surface of the tongue affected. The dorsum was the most common tongue surface affected in 22/32 (68.8%) cases while the ventral surface was involved in 10/32 (31.2%) cases.

Furthermore, only 35/81 (43.3%) cases recorded the duration of disease from onset of disease to time of hospital presentation. All the patients presented within one to 84 months of onset of symptom, with a median duration of 6 months (Interquartile range 9 months). Also, 65/81 (80.2%) cases had tumour size documented; either clinical or gross surgical specimen, in which only 3 cases (4.6%) had tumour size greater than 6.5 cm. Mean tumour size obtained was 2.9 ± 1.9 cm in the widest dimension, while the size range was 0.8 to 8 cm. Additionally, clinical impression of a benign lesion was made in 33/81 (40.7%) cases and these were mainly constituted by haemangioma 12/

Table 1: Characterization of TASPS in Ibadan

Case	Gender	Age	Site	Surface	Duration	Size (cm)	Treatment	Follow up	Status at follow up
1	Male	29	Sulcus terminalis	Dorsum	3 months	NR	NR	NR	LTFU
2	Male	6	Anterior	Dorsum	3 months	6	Surgery	13 months	FOD
3	Female	34	Anterior	Dorsum	6 months	5	None	19 months	DOD
4	Male	17	Posterior	Dorsum	48 months	NS	None	12 months	AWD

NR – No record; LTFU – Lost to follow up; FOD – Free of disease; DOD – Died of disease; AWD – Alive with disease

In all, 77 cases from 49 articles and four cases from records of Oral Pathology Department, UCH, Ibadan (totaling 81 cases) were used. Table 2 shows a list of the publications and the number of cases.^{3,5,17,18,26-69} Asian studies accounted for 35 (43.2%) cases, while North American and European studies recorded 25 (30.9%) and 12 (14.8%) cases respectively (Figure 4). There was a slight female preponderance of 1.1 and

33 (36.4%) followed by granular cell myoblastoma/tumour 6/33 (18.2%) and dermoid cyst 2/33 (6%). Only 54/81 (66.7%) cases recorded the presence or absence of tumour metastasis either at presentation or at any point during treatment. Tumour metastasis was present in 14/54 (25.9%) cases, while it was not seen in 40/54 (74.1%) cases. Also, the most common site of tumour metastasis were regional lymph nodes

Table 2: Characteristics of reviewed literature of TASP

S/N	Year	Author(s)	Country	Age & Gender	Site & Surface	Size (cm)	Treatment	Follow up (Months)	Status at follow-up
1	1952	Christopherson <i>et al.</i>	USA	12/F	Base	5cm (Gross)	Surgery	60 months	NED
2	1979	Spector <i>et al.</i>	USA	17/F	Base	4.8cm	Surgery, RTH Chemotherapy,	60 months	DOD
3	1983	King and Fee	USA	5/F	Anterior	1cm	Surgery	24 months	FOD
4	1984	Komori <i>et al.</i>	Japan	11/F	Base	2.5cm	Surgery	61 months	FOD
5	1984	Chaudhry <i>et al.</i>	India	0.3/F	Dorsum	2cm	Surgery	-	-
6	1985	Sawyer <i>et al.</i>	Nigeria	16/F	Base/Ventral	-	Surgery	6 months	FOD
7	1987	Donald	USA	19/F	Torgue NOS	-	Surgery, RTH	24 months	FOD
8	1989	Simmons <i>et al.</i>	USA	1.6/F	Dorsum	1.5cm	Surgery	43 months	FOD
9	1989	Cetik <i>et al.</i>	Turkey	13/F	Dorsum	1.5cm	Surgery, RTH Chemotherapy	12 months	FOD
10	1990	Takita <i>et al.</i>	Japan	19/M	Dorsum	2.8cm (Scat)	Surgery, Chemotherapy	36 months	FOD
11	1990	Matsumo <i>et al.</i>	Japan	6/M	Torgue NOS	3cm	Surgery, Chemotherapy	27 months	AWD
12	1993	Carson <i>et al.</i>	USA	64/M	Base	8cm	Chemotherapy,RTH	36 months	DOD
13	1993	Ooi <i>et al.</i>	Singapore	21/M	Anterior-base/ Dorsum	4cm	Surgery	4 months	FOD
14	1998	Hunter <i>et al.</i>	USA	3/F	Torgue NOS	-	Surgery	48 months	FOD
15	1999	Bentley <i>et al.</i>	UK	5/F	Base	6.5cm	Surgery, RTH Chemotherapy	43 months	FOD
16	2000	Casanova <i>et al.</i> (1)	Italy	18/F	Torgue NOS	-	Surgery	13 months	FOD
17	2000	Casanova <i>et al.</i> (2)	Italy	5/F	Torgue NOS	-	Chemotherapy, Surgery	139 months	FOD
18	2000	Yoshida <i>et al.</i>	Japan	2/F	Dorsum	2cm	Surgery, Chemotherapy	86 months	FOD
19	2003	Aiken and Stone	USA	F/34	Base	-	Surgery, Chemotherapy	24 months	MD
20	2004	do Nascimento Souza <i>et al.</i>	Brazil	13/F	Lateral/Dorsum	3cm	Surgery, Chemotherapy	60 months	FOD
21	2004	Fanburg-Smith <i>et al.</i> (1)	USA	3/F	Lateral	2.5cm	Surgery, Chemotherapy	132 months	NED
22	2004	Fanburg-Smith <i>et al.</i> (2) (Castle 1999)	USA	3/M	Lateral	0.8cm	Surgery	48 months	NED
23	2004	Fanburg-Smith <i>et al.</i> (3)	USA	3/F	Lateral	-	Surgery	120 months	NED
24	2004	Fanburg-Smith <i>et al.</i> (4)	USA	5/M	Base	-	Surgery	132 months	FOD
25	2004	Fanburg-Smith <i>et al.</i> (5) (Clisen 1976)	USA	5/F	Lateral	5cm	Surgery	384 months	NED
26	2004	Fanburg-Smith <i>et al.</i> (6)	USA	5/F	Mid-portion	1cm	Surgery	264 months	FOD

Table 2: Cont'd

27	2004	Fanburg-Smith <i>et al.</i> (7)	USA	5/F	Lateral	-	Surgery	-	-
28	2004	Fanburg-Smith <i>et al.</i> (8)	USA	6/M	Tongue NOS	-	Surgery	-	-
29	2004	Fanburg-Smith <i>et al.</i> (9)	USA	6/M	Mid-portior	2.5cm	Surgery	336 months	FOD
30	2004	Fanburg-Smith <i>et al.</i> (10)	USA	7/M	Ventral	1.3cm	Surgery	324 months	FOD
31	2004	Fanburg-Smith <i>et al.</i> (11)	USA	7/M	Lateral	2.5cm	Surgery, Chemotherapy	192 months	NED
32	2004	Fanburg-Smith <i>et al.</i> (12)	USA	17/M	Base	2.5cm	Surgery	300 months	NED
33	2004	Fanburg-Smith <i>et al.</i> (13)	USA	20/M	Base	1cm	Surgery	-	-
34	2004	Fanburg-Smith <i>et al.</i> (14)	USA	21/F	Lateral	3cm	Surgery	-	-
35	2005	Kim <i>et al.</i> (1)	Korea	16/M	Tongue NOS	-	Surgery	6 months	FOD
36	2005	Kim <i>et al.</i> (2)	Korea	4/F	Tongue NOS	-	Surgery	8 months	FOD
37	2005	Kanhere <i>et al.</i> (1)	India	6/M	Tongue NOS	1.5cm	Surgery	18 months	FOD
38	2005	Kanhere <i>et al.</i> (2)	India	42/M	Tongue NOS	3.5cm	Surgery, RTH	21 months	RD
39	2005	Kanhere <i>et al.</i> (3)	India	18/M	Tongue NOS	4.0cm	Surgery	24 months	FOD
40	2005	Kanhere <i>et al.</i> (4)	India	43/M	Tongue NOS	2.5cm	Surgery, RTH	72 months	AWD
41	2006	Correia-Silva <i>et al.</i>	Brazil	17/F	Anterior/Dorsum	2cm	Surgery	12 months	FOD
42	2006	Ryu <i>et al.</i>	Korea	3/F	Lateral/Dorsum	2cm	Surgery	32 months	FOD
43	2007	Ragunandhan <i>et al.</i>	India	13/F	Base	2.5cm	Surgery, RTH	6 months	FOD
44	2008	Tapisiz <i>et al.</i>	Turkey	18/F	Dorsum	4.5cm	Chemotherapy	-	-
45	2009	Rodriguez-Velasco <i>et al.</i>	Mexico	2/F	Lateral	1.5cm	Chemotherapy	34 months	FOD
46	2009	Baglam <i>et al.</i>	Turkey	18/F	Base	6cm	Surgery, RTH	10 months	DOD
47	2010	Noussios <i>et al.</i>	Greece	3/M	Dorsum	3.3cm	Chemotherapy	-	-
48	2010	Kumar <i>et al.</i>	India	7/M	Lateral/Dorsum	2cm	Surgery	42 months	FOD
49	2010	Eley <i>et al.</i>	UK	24/M	Lateral	1cm	Surgery, Chemotherapy	11 months	FOD
50	2011	Abarasi <i>et al.</i>	India	25/M	Anterior/Dorsum	3cm	Surgery	12 months	FOD
51	2011	Conde <i>et al.</i>	Spain	5/F	Base/Ventral	4cm	Surgery	36 months	FOD
52	2012	Rekhi <i>et al.</i> (1)	India	24/F	Tongue NOS	-	Surgery, Chemotherapy	36 months	FOD
53	2012	Rekhi <i>et al.</i> (2)	India	18/F	Tongue NOS	-	Surgery	-	-
54	2013	A-gyris <i>et al.</i>	Greece	4/M	Tongue NOS	-	Surgery	-	-
55	2013	Adeyemi <i>et al.</i>	Nigeria	27/M	Sulcus terminalis/ Dorsum	2cm	Surgery	7 months	FOD
56	2014	Kinger <i>et al.</i>	India	14/M	Ventral	6cm	Surgery	-	LIFU
57	2014	Meng <i>et al.</i>	China	4/M	Anterior/Dorsum Root	4cm 4.5cm (CT)	Surgery Chemotherapy, RTH, Surgery	- 30 months	- FOD

Table 2: Cont'd

58	2014	Liu <i>et al.</i>	Taiwan	27/F	Ventral and FOM	5cm	Surgery, RTH	24 months	FOD
59	2015	Wang <i>et al.</i> (1)	China	20/F	Base	2.5cm	Surgery	34 months	NED
60	2015	Wang <i>et al.</i> (2)	China	3/F	Base	3.5cm	Surgery	10 months	NED
61	2015	Wang <i>et al.</i> (3)	China	11/M	Dorsum	3cm	Surgery	14 months	NED
62	2015	Wang <i>et al.</i> (4)	China	14/F	Ventral and FOM	5cm	Surgery	15 months	NED
63	2015	Wang <i>et al.</i> (5)	China	28/F	Ventral and FOM	6cm	Surgery, RTH	21 months	AWD
64	2015	Wang <i>et al.</i> (6)	China	4/M	Ventral and FOM	6.5cm	Surgery	25 months	NED
65	2015	Wang <i>et al.</i> (7)	China	7/M	Base	4cm	Surgery	29 months	NED
66	2015	Wang <i>et al.</i> (8)	China	16/F	Base	3.3cm	Surgery	35 months	NED
67	2015	Wang <i>et al.</i> (9)	China	10/M	Base	3.5cm	Surgery	77 months	NED
68	2015	Wang <i>et al.</i> (10)	China	6/F	Ventral and FOM	5cm	Surgery	60 months	NED
69	2017	Chopra and Tanveer	India	35/M	Lateral	2cm	Chemotherapy, Surgery	-	-
70	2017	Yoshihiro <i>et al.</i>	Japan	23/M	Tongue NOS	-	Surgery, Chemotherapy	4 months	MD
71	2017	Chatura <i>et al.</i>	India	8/F	Base	3cm	Surgery	-	LTFU
72	2017	Katz <i>et al.</i>	USA	1.8/M	Ventral	2cm	Surgery	60 months	FOD
73	2019	Ruffle <i>et al.</i>	UK	0.9/F	Anterior	1.6cm (MRI)	Surgery	14 months	FOD
74	2019	Leszczynska <i>et al.</i>	USA	6/M	Dorsum	1.7cm (CI)	Surgery	36 months	FOD
75	2019	Hsu <i>et al.</i>	Taiwan	3/M	Posterior/Dorsum	1.2cm	Surgery	1 month	FOD
76	2019	Alegria-Landa <i>et al.</i>	Spain	53/M	Anterior	2cm	Surgery	-	-
77	2019	Fouad <i>et al.</i>	Morocco	13/M	Tongue NOS	7.4cm (Gross)	Surgery, Chemotherapy	12 months	DOD
78	Present case 1		Nigeria	29/M	Sulcus terminalis/ Dorsum	-	-	-	LTFU
79	Present case 2		Nigeria	6/M	Anterior/Dorsum	6cm	Surgery	13 months	FOD
80	Present case 3		Nigeria	34/F	Anterior/Dorsum	5cm	No treatment	12 months	DOD
81	Present case 4		Nigeria	17/M	Posterior/Dorsum	-	No treatment	16 months	AWD

NB: No evidence of disease (NED) was analyzed as free of disease (FOD) for standardization. Cases reported by Fanburg-Smith *et al.*, that were recorded as "Alive" were assumed to be free of disease except they were specified as "Alive with disease".

M, Male, F, female, NOS, not otherwise specified, RTH, radiotherapy, FOM, floor of mouth, FOD, free of disease, NED, no evidence of disease, AWD, alive with disease, MD, metastatic disease, RD, recurrent disease, DOD, died of disease, LTFU, lost to follow up, - no data.

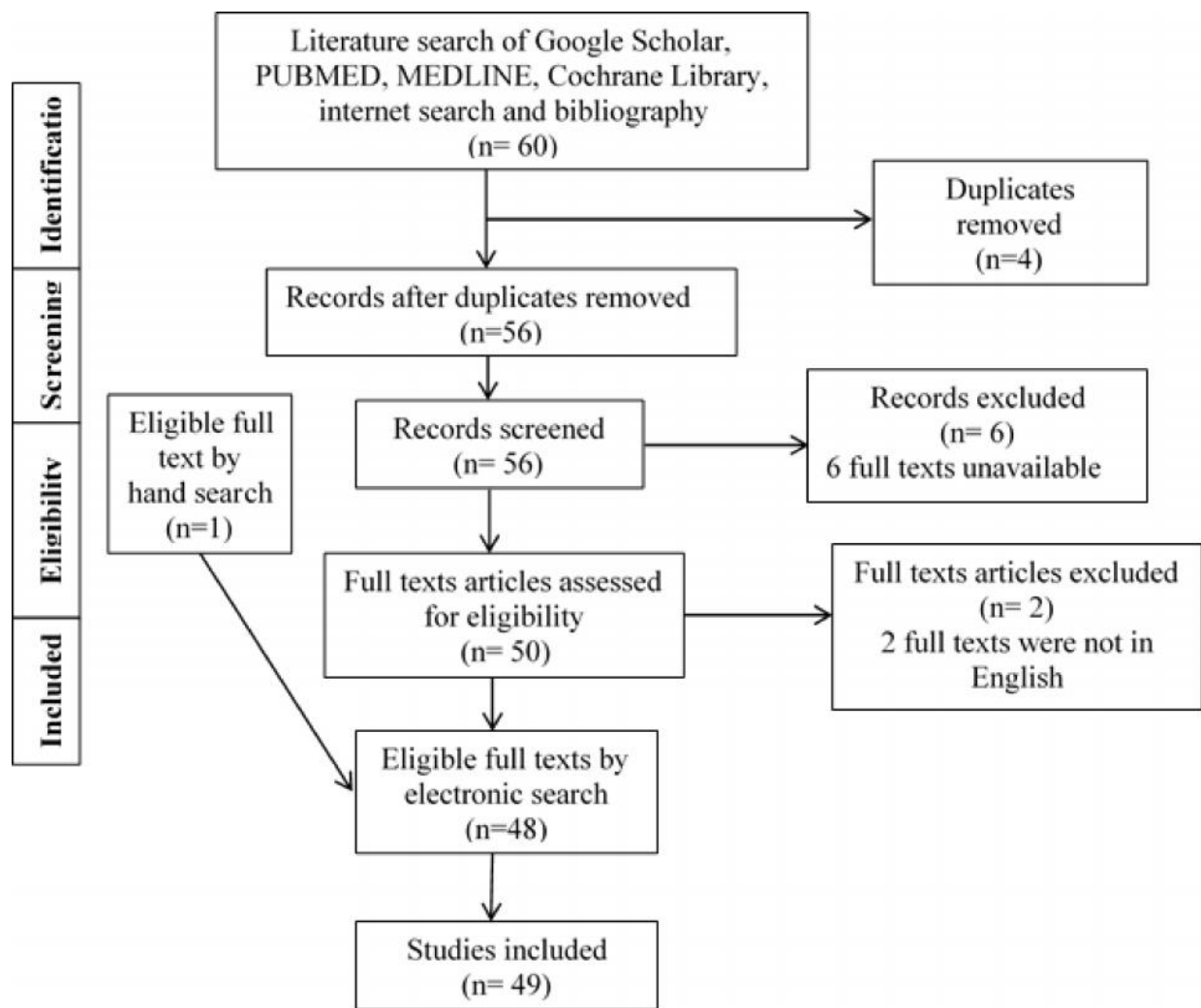


Figure 1: Flow chart for scoping review

Table 3: Age distribution of cases in decades

Years in decade	Frequency	Percentage
0-9	38	46.9
10-19	24	29.6
20-29	12	14.8
30-39	3	3.7
40-49	2	2.5
50-59	1	1.2
60-69	1	1.2
Total	81	100.0

and the lungs, both recording 6/14 (42.8%) and 4/14 (28.6%) respectively. The lungs and the liver as well as the lungs and lymph nodes were affected in one case each, while disseminated disease occurred in 2/14 (14.3%) cases.

Immunohistochemical studies became more established in the last two to three decades of this review and were performed in 37/81 (45.6%) cases in which 33/37 (89.2%) cases were stained using the

Table 4: Treatment modalities of TASPS cases

Treatment type	Frequency	Percentage
Surgery only	51	63.0
Surgery and chemotherapy	11	13.6
Surgery and radiotherapy	6	7.4
Surgery, chemotherapy and radiotherapy	5	6.2
No treatment	2	2.5
Chemotherapy only	2	2.5
Chemotherapy and radiotherapy	1	1.2
Chemotherapy, then surgery	1	1.2
Chemotherapy, radiotherapy, surgery and brachytherapy	1	1.2
Not specified	1	1.2
Total	81	100.0

following antibodies: Transcription Factor E3 (TFE3) - (8/24.2%); Neuron Specific Enolase (NSE) - (8/24.2%); desmin (7/21.2%); actin (5/15.2%) and vimentin (5/15.2%) while four cases stained negative to all the immunohistochemical stains used. Interestingly, TFE3 and NSE were both expressed 7

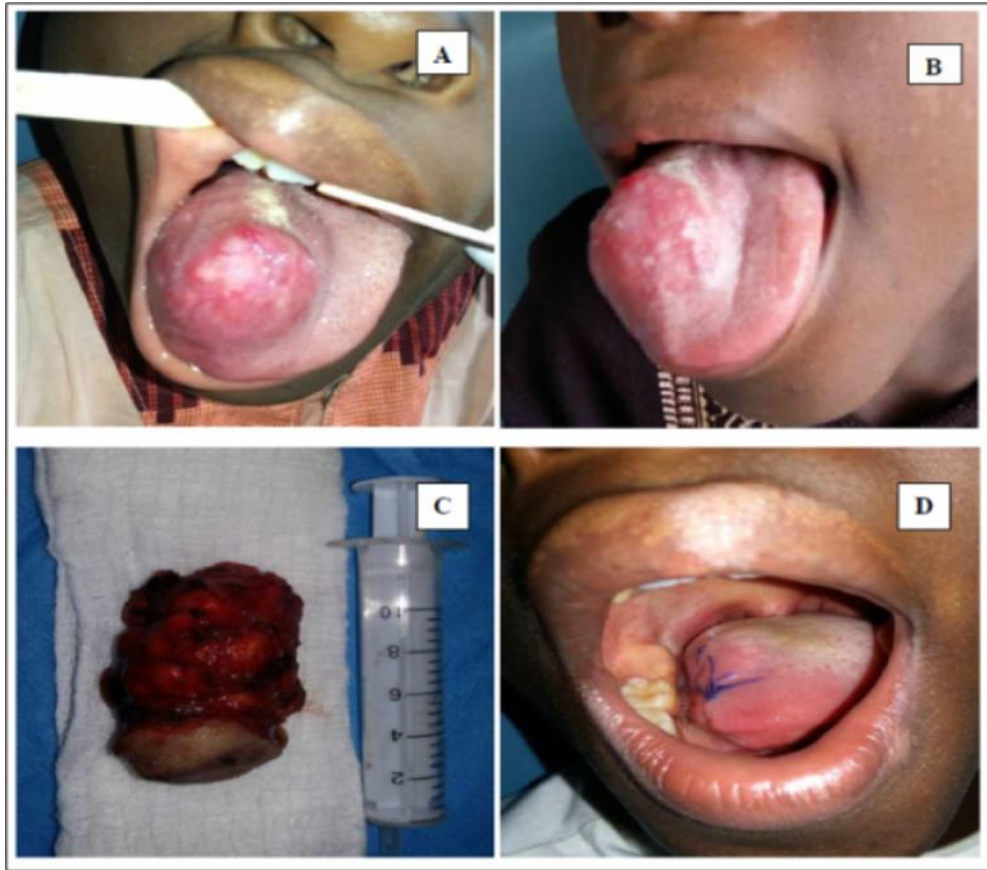


Figure 2: Clinical pictures of 6 year old male, A and B shows dorsal swelling of the tongue, C shows surgical specimen and D shows tongue one-week post operatively.

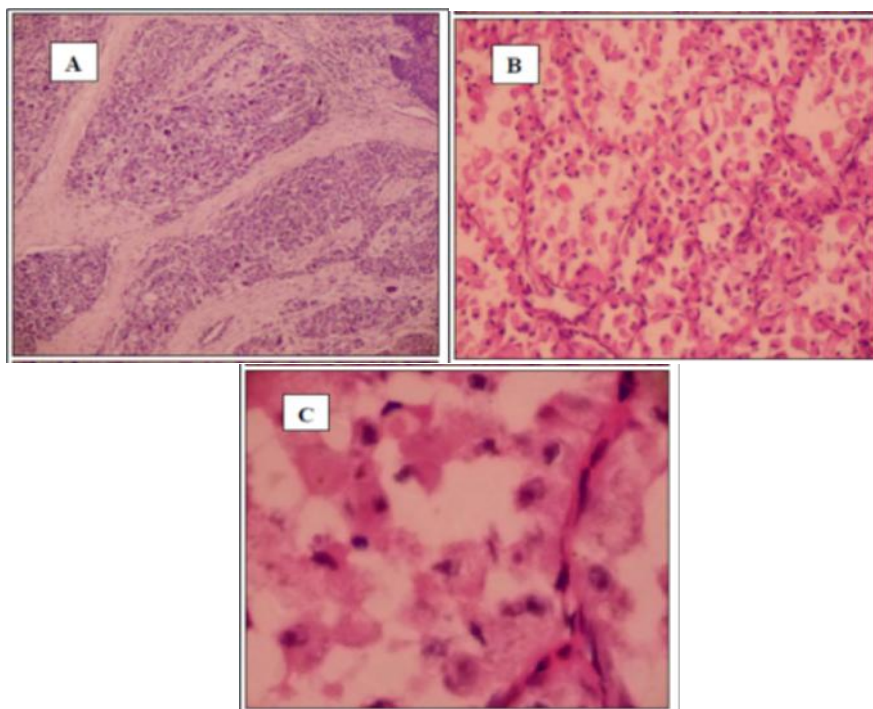


Figure 3: Histopathology of TASPS cases in Ibadan. Photomicrograph shows (A) - solid pattern having tissue disposed in organoid arrangement, separated by vascularized fibrous septae H & E X 40; (B) - shows large oval to round eosinophilic cells H & E X 100 and (C) – shows non-cohesive individual cells having abundant granular cytoplasm H & E X 400

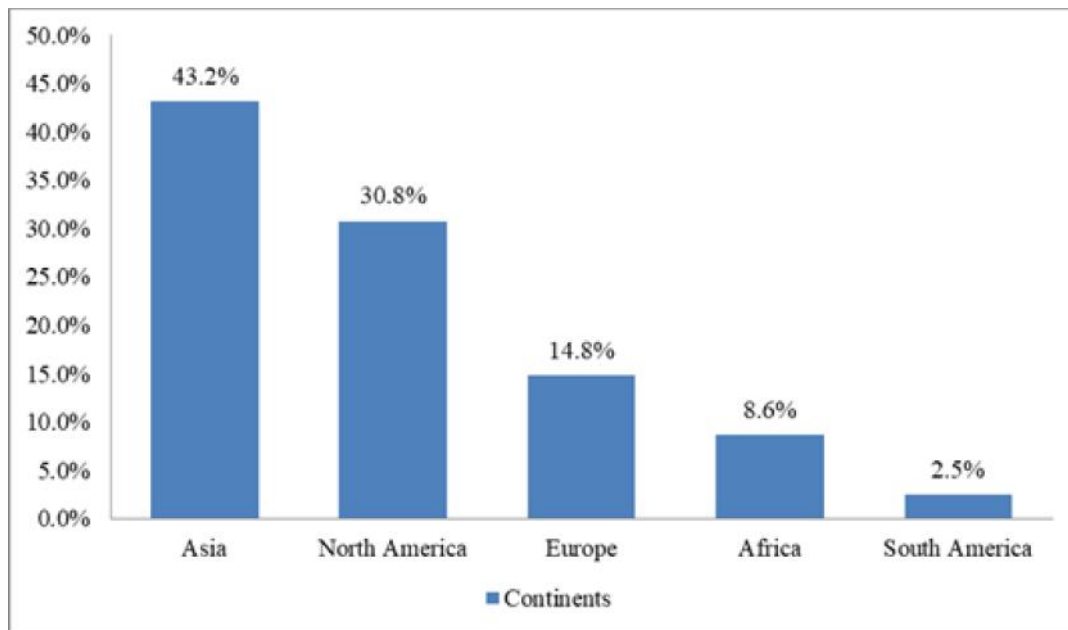


Figure 4: Distribution of TASPSP cases according to continent

out of 8 cases (expression rate of 87.5%) while desmin, actin and vimentin were expressed 5 out of 7 (71.4%), 4 out of 5 (80%) and 3 out of 5 (60%) cases respectively. Polymerase chain reaction was also used in three instances to detect the presence of TFE3.

Most common treatment modality was surgery in 51 (63%) cases, followed by surgery + chemotherapy in 11 (13.6%) cases and surgery + radiotherapy in 6 (7.4%) cases (Table 4). Subsequently, 42/51 (82.4%) cases that were managed by surgery alone were free of disease at ≤ 5 years of follow up while 9/51 (17.6%) were free of disease at >5 years of follow up. All the patients (4 cases) that had follow up for over 300 months, who had surgery alone, had either “no evidence of the disease” or “were free of the disease” at the last follow up.

DISCUSSION

The present study presents an effort to characterize TASPSP by giving a synopsis of its clinico-pathologic features from when it was first reported till date and present cases seen at our center. Our major findings include the following: Asian studies dominated the cases seen in this study, with Wang *et al.*⁶⁴ contributing 10 cases having tongue involvement out of a series of 18 patients with ASPSP of the oral and maxillofacial region. Increased incidence of TASPSP on the Asian continent may be due to the relatively large population of Asia. Tongue ASPSP slightly affected the female gender more commonly and about 76.5% of cases were diagnosed in the first two decades of life, subsequently showing a steady decline in incidence with advancing age. The base of the tongue is the most

common location involved, while the dorsum is the most frequently affected surface. Interestingly, it was initially considered to be a benign lesion in some case reports and tumour metastasis occurred in 25.9% of cases that reported presence of metastasis. Also, TFE3 and NSE immunohistochemical stains had equal expression rates while surgery was the most common treatment modality.

In the present review, some findings differed from those in a previous review of 14 lingual ASPSP by Fanburg-Smith *et al.*¹⁸ which to the best of our knowledge was the largest series on TASPSP in English literature. Slight female preponderance was seen in the present study which differed from a male preponderance reported by Fanburg-Smith *et al.*¹⁸ Some authors have previously referred to ASPSP as a disease of childhood while some have referred to it as a disease of childhood and adolescence^{4,6,18}. In the present study, majority of ASPSP occurred in the first and second decade of life but few also occurred in other age groups up to the 7th decade. Also, Fanburg-Smith *et al.*¹⁸ recorded a median age of five years while this study recorded a median age of 11 years. Similarly, the age range in this review was 11 months to 64 years while Fanburg-Smith *et al.*¹⁸ recorded a range of 3 to 21 years. The findings in this review, however concurs with the findings in a study of ASPSP of the oral cavity by Shelke *et al.*²⁴ where an age range of 1.5 – 64 years was reported. Similarly, the finding in this study on female predilection is in agreement with the outcome in the study of Shelke *et al.*²⁴ where a female predilection for TASPSP was also reported. It is probable that our larger sample size comprising of

subjects from wider and diverse socio-cultural-geographic background may be responsible for the noted differences and may be more representative of the characteristic of TASP. S.

Additionally, the findings of the base and dorsum of the tongue, as the prevalent location and surface affected in this study, were in line with the results obtained by Shelke *et al.*²⁴. Much is yet to be understood in the preference for the tongue by ASP. S. in the head and neck region and the predominance of the involvement of the base as well as the dorsal surface of the tongue. The base of tongue serves as the posterior opening of the oral cavity as well as the access to the pharynx and esophagus, and the lower aspect of the nasopharynx. It is composed of sub-mucosal lymphoid tissue (lingual tonsils) and deep tongue muscles in charge of movement. Also, this region may play a role as a sump area for carcinogens and irritants. Whether a link exists between the anatomy of the base of the tongue and the preference of TASP. S. for this location would be a useful focus of future research. Also, most of the ASP. S. in this review were relatively small in size, in agreement with the previous study by Fanburg-Smith *et al.*¹⁸. Due to the location and function of the tongue, it is likely to have an early presentation with a small tumour size either due to discomfort, abnormal sensation, or interference with function which may make the patient seek help early.

ASP. S. like many soft tissue tumours lack specific immunohistochemical markers, which reflected in the use of a wide range of antibodies in various reports collated in this study. ASP. S. has been previously reported to show infrequent immunoreactivity for desmin⁷⁰ and MyoD1⁷¹ suggesting skeletal muscle differentiation. Our findings in this study revealed that various antibodies were randomly expressed in the different studies.

Nevertheless, ASP. S. is now believed to be a specific chromosomal alteration, der(17)t(X:17)(p11;q25), owing to the fusion of the TFE3 transcription factor gene with the alveolar soft part sarcoma critical region 1 (ASPSCR1)⁶. The use of real-time polymerase chain reaction and fluorescent in situ hybridization in identifying fusion transcript ASPSCR1-TFE3 and TFE3 rearrangement respectively, are regarded as efficient ways for diagnosis⁶. Similarly, this same fusion gene has been implicated in a section of translocation associated renal cell carcinomas (RCCs)⁶. However, the translocation in ASP. S. is unbalanced while that of translocation associated RCCs are balanced.⁶ Also, the ASPSCR1-TFE3 fusion protein plays the role of a deviant transcription factor leading to the activation of the MET signaling pathway known to stimulate angiogenesis and

cell proliferation⁶. In addition, antibodies to TFE3 exhibit nuclear positivity in ASP. S.; similar to findings in some translocation-associated renal cell carcinomas (RCCs), perivascular epithelioid cell neoplasm (PEComa) and granular cell tumours.⁷²⁻⁷⁵

Curiously in this study, antibodies to TFE3 and NSE were used in equal number of cases and expression rate was 87.5% for each. This finding suggests that more studies would be needed to verify if NSE has a role as a reliable marker for ASP. S.

Alveolar soft part sarcoma was previously reported to have a high rate of metastasis especially to the lungs, bone and the brain.^{2,7} However, in this review, the reported rate of metastasis for TASP. S. was found to be lower than expected at 25.9% of studies that reported metastasis. Also one of the cases that presented in our center who was yet to have any form of treatment, has lived with the disease for sixty months without evidence of metastasis. Adjudging that the presence of metastasis is usually seen as an indicator for malignancies, it is unclear whether TASP. S. represents an entity with better prognosis than ASP. S. in other parts of the body.

Furthermore, surgical management was the most common treatment modality employed in many studies in this review; either alone or in combination with other treatment modalities. All cases (four in all) that were followed up for over 300 months with tumour sizes ranging between 1.3 cm to 5 cm, had surgery alone and had no evidence of the disease or metastasis as at the last follow up. As opined by Fanburg-Smith *et al.*¹⁸, early diagnosis and small tumour size may be factors that influence the relatively good outcome associated with ASP. S.

Study limitations

The differences in the mode of presentation of the cases posed a challenge in data retrieval and analysis since there is no uniform benchmark for case reports and series. This led to heterogeneity of results, making it challenging to pool findings from the studies included and to draw definitive conclusions from this study. Also, the cases described here may not constitute the entirety of TASP. S. (perhaps due to under-reporting and inaccessible full articles). However, they probably do comprise the majority of cases worldwide.

CONCLUSION

Summarily, this study has provided an up to date brief of TASP. S. Tongue ASP. S. slightly affected the female gender more commonly and occurred more in the first two decades of life. Also, the base of the tongue was the most common location affected while surgical

management was mostly used for treatment and cases managed by surgery alone were free of disease at ≤ 5 years of follow up. Use of gold standard investigative tools for diagnosis and for follow up will allow for better appraisal of research findings. Longitudinal follow up of cases will also help in better understanding of this disease entity as well as the optimum treatment modality. Thus, clinicians should be suspicious of indolent appearing tongue lesions and expedite histologic assessment even when a benign lesion is suspected. This is more so when a hemorrhagic tongue swelling is being considered.

Declaration of Conflicting Interests

The authors declared no potential conflicts of interest with respect to the research, authorship, and/or publication of this article.

Funding

The authors received no financial support for the research, authorship, and/or publication of this article.

ACKNOWLEDGMENTS

The authors thank Dr. Yomi Baruwa, Dr. Wale Dudubo, Dr. Dipo Ajayi and Dr. Toks Abiose for their assistance in the literature search.

REFERENCES

- Ferrari A**, Sultan I, Huang TT, *et al.* Soft tissue sarcoma across the age spectrum: a population-based study from the Surveillance Epidemiology and End Results database. *Pediatr Blood Cancer* 2011; 57 (6):943–949.
- Weiss SW**, Goldblum JR. *Enzinger and Weiss's soft tissue tumours*. 5th Ed., Philadelphia PA: Mosby, 2008, p.1183.
- Christopherson WM**, Foote FW Jr, Stewart FW. Alveolar soft part sarcoma: structurally characteristic tumours of uncertain histogenesis. *Cancer* 1952; 5:100-101.
- Fletcher CDM**, Bridge JA, Hogendoorn PCW, Mertens F, editors. *Pathology and genetics of tumours of soft tissue and bone: In World Health Organization classification of tumours; Vol 5*. Lyon, France: IARC Press, 2013, p 218.
- Hunter BC**, Ferlito A, Devaney KO, Rinaldo A. Alveolar soft part sarcoma of the head and neck region. *Ann Otol Rhinol Laryngol* 1998; 107:810-814.
- Jaber OI**, Kirby PA. Alveolar Soft Part Sarcoma. *Arch Pathol Lab Med* 2015; 139: 1459-1462.
- Portera CA Jr**, Ho V, Patel SR, *et al.* Alveolar soft part sarcoma: clinical course and patterns of metastasis in 70 patients treated at a single institution. *Cancer* 2001; 91(3): 585–591.
- Ord'óñez NG**. Alveolar soft part sarcoma: a review and update. *Adv Anat Pathol* 1999; 6 (3):125–139.
- Batsakis JG**. Alveolar soft-part sarcoma. *Ann Otol Rhinol Laryngol* 1988; 97:328–329.
- Lieberman PH**, Brennan MF, Kimmel M, *et al.* Alveolar soft-part sarcoma: a clinico-pathologic study of half a century. *Cancer* 1989; 63(1):1–13.
- Suh JS**, Cho J, Lee SH, *et al.* Alveolar soft part sarcoma: MR and angiographic findings. *Skeletal Radiol* 2000; 29(12): 680–689.
- Temple HT**, Scully SP, O'Keefe RJ, *et al.* Clinical presentation of alveolar soft-part sarcoma. *Clin Orthop Relat Res* 1994; 12: 213–218.
- Lorigan JG**, O'Keefe FN, Evanz HL, Wallace S. The radiologic manifestations of alveolar soft-part sarcoma. *AJR Am J Roentgenol* 1989; 153 (2):335–339.
- Auerbach HE**, Brooks JJ. Alveolar soft part sarcoma. A clinicopathologic and immunohistochemical study. *Cancer* 1987; 60: 66-73.
- Zarrin-Khameh N**, Kaye KS. Alveolar soft part sarcoma. *Arch Pathol Lab Med* 2007; 131: 488-491.
- Folpe AL**, Deyrup AT. Alveolar soft-part sarcoma: a review and update. *J Clin Pathol* 2006; 59:1127–1132.
- Adeyemi BF**, Ogun GO, Lawal AO, *et al.* Sublingual alveolar soft part sarcoma: a case report. *Ghana Dental Journal* 2013; 10: 1: 6-7.
- Fanburg-Smith JC**, Miettinen M, Folpe AL, *et al.* Lingual alveolar soft part sarcoma; 14 cases: novel clinical and morphological observations. *Histopathology* 2004; 45, 526–527.
- Souza KCN**, Faria PR, Costa IM, *et al.* Oral alveolar soft-part sarcoma: review of literature and case report with immunohistochemistry study for prognostic markers. *Oral Surg Oral Med Oral Pathol Oral Radiol Endod* 2005; 99 (1): 64–70.
- Yigitbasi OG**, Guney E, Kontas O, *et al.* Alveolar soft part sarcoma: report of a case occurring in the sinonasal region. *Int J Pediatr Otorhinolaryngol* 2004; 68(10): 1333–1337.
- Silbergleit R**, Agrawal R, Savera AT, Patel SC. Alveolar soft-part sarcoma of the neck. *Neuroradiology* 2002; 44 (10): 861–863.
- Inci E**, Korkut N, Erem M, Kalekoglu N. Alveolar soft tissue sarcoma. *HNO* 2004; 52 (2):145–149.
- Bentley RP**, Wake MJ, Raafat F. Alveolar soft part sarcoma of the tongue. *Br J Oral Maxillofac Surg* 1999; 37:451–454.
- Shelke P**, Sarode GS, Sarode SC, *et al.* Alveolar soft-part sarcoma of the oral cavity: a review of literature. *Rare Tumours* 2018; 10: 1–8. doi.org/10.1177/20363613188109.

25. **Tricco AC**, Lillie E, Zarin W, *et al.* PRISMA extension for scoping reviews (PRISMA_{ScR}): checklist and explanation. *Ann Intern Med* 2018; 169: 467–473.
26. **Spector R**, Travis L, Smith, J. Alveolar soft part sarcoma of the head and neck. *Laryngoscope* 1979; 89: 1301-1306.
27. **King VV**, Fee WE, Jr. Alveolar soft part sarcoma of the tongue. *Am J Otolaryngol* 1983; 4: 363-6.
28. **Komori A**, Takeda Y, Kakiichi T. Alveolar soft-part sarcoma of the tongue. Report of a case with electron microscopic study. *Oral Surg Oral Med Oral Pathol* 1984; 57: 532–539.
29. **Chaudhry A**, Lin C, Lai S, Yamane G. Alveolar soft part sarcoma of the tongue in a female neonate. *J Oral Med* 1984; 39: 2-7.
30. **Sawyer DR**, Ajagbe HA, Abiose BO, Daramola JO. Alveolar soft-part sarcoma of the oral cavity. Report of a case. *J Oral Med.*1985; 40:139–141.
31. **Donald P**. Alveolar soft part sarcoma of the tongue. *Head Neck Surg* 1987; 9: 172-178.
32. **Simmons WB**, Haggerty HS, Ngan B, Anonsen CK. Alveolar soft part sarcoma of the head and neck. A disease of children and young adults. *Int J Pediatr Otorhinolaryngol* 1989; 17: 139-153.
33. **Cetik F**, Ozsahinoglu C, Kivanc F, Secinti E. Alveolar soft part sarcoma of the tongue. *J Laryngol Otol* 1989; 103: 952–954.
34. **Takita MA**, Morishita M, Iriki-in M, *et al.* Alveolar soft-part sarcoma of the tongue: report of a case. *Int J Oral Maxillofac Surg* 1990; 19:110-112.
35. **Matsuno Y**, Mukai K, Itabashi M, *et al.* Alveolar soft part sarcoma. A clinicopathologic and immunohistochemical study of 12 cases. *Acta Pathol Jpn* 1990; 40:199–205.
36. **Carson HJ**, Tojo DP, Ghosh L, Molnar ZV. Primary alveolar soft part sarcoma of the tongue of an elderly man. A case report and review of the literature. *Oral Surg Oral Med Oral Pathol.* 1993; 76: 62-67.
37. **Ooi LP**, Sim CS, Peck RH, Soo KC. Alveolar soft part sarcoma of the tongue: a case report. *Aust N Z J Surg* 1993; 63: 240-242.
38. **Casanova M**, Ferrari A, Bisogno G, *et al.* Alveolar soft part sarcoma in children and adolescents: a report from the soft tissue sarcoma Italian cooperative group. *Ann Oncol.* 2000; 11: 1445-1449.
39. **Yoshida K**, Kurauchi J, Shirasawa H, Kosugi I. Alveolar soft part sarcoma of the tongue: report of a case. *Int J Oral Maxillofac Surg* 2000; 29:370-372.
40. **Aiken AH**, Stone JA. Alveolar soft-part sarcoma of the tongue. *AJNR Am J Neuroradiol.* 2003; 24: 1156–1158.
41. **do Nascimento Souza KC**, Faria PR, Costa IM, *et al.* Oral alveolar soft-part sarcoma: review of literature and case report with immunohistochemistry study for prognostic markers. *Oral Surg Oral Med Oral Pathol Oral Radiol Endod.* 2005; 99: 64–70.
42. **Kim HS**, Lee HK, Weon YC, Kim HJ. Alveolar soft-part sarcoma of the head and neck: clinical and imaging features in five cases. *AJNR Am J Neuroradiol.* 2005; 26: 1331–1335.
43. **Kanhere HA**, Pai PS, Neeli SI, *et al.* Alveolar soft part sarcoma of the head and neck. *Int J Oral Maxillofac.Surg* 2005; 34: 268–272.
44. **Correia-Silva J**, Duarte ECB, Lacerda JT, *et al.* Alveolar soft part sarcoma of the tongue. *Oral Oncol Extra* 2006; 42: 241– 243.
45. **Ryu J**, Kwon Y, Park B, Jung Y. Lingual alveolar soft part sarcoma treated only by conservative resection. *Int J Pediatr Otorhinolaryngol Extra.* 2006; 1: 243-248.
46. **Raghunandhan S**, Murali S, Nagasundaram J, *et al.* Alveolar soft part sarcoma of tongue base - a rare presentation of a rare tumour. *Indian J Otolaryngol Head Neck Surg* 2007; 59: 393–395.
47. **Tapisiz OL**, Gungor T, Ustunyurt E, *et al.* An unusual case of lingual alveolar soft part sarcoma during pregnancy. *Taiwan J Obstet Gynecol* 2008;47 (2): 212–214.
48. **Rodriguez-Velasco A**, Ferman-Cano F, Cerecedo-Diaz F. Rare tumour of the tongue in a child: alveolar soft part sarcoma. *Pediatr Dev Pathol* 2009; 12: 147–151.
49. **Baglam T**, Kalender ME, Durucu C, *et al.* Alveolar soft part sarcoma of the tongue. *J Craniofac Surg* 2009; 20: 2160-62.
50. **Noussios G**, Chouridis P, Petropoulos I, *et al.* Alveolar soft part sarcoma of the tongue in a 3-year-old boy: a case report. *J Med Case Rep* 2010; 4:130. doi: 10.1186/1752-1947-4-130.
51. **Kumar M**, Patne S, Vishwanath A, Hasan Z. Lingual alveolar soft part sarcoma in a child managed successfully with surgery and chemotherapy. *Indian J Cancer* 2010; 47: 234-235.
52. **Eley KA**, Afzal T, Shah KA, Watt-Smith SR. Alveolar soft-part sarcoma of the tongue: report of a case and review of the literature. *Int J Oral Maxillofac Surg* 2010; 39: 824–826.
53. **Anbarasi K**, Sathasivasubramanian S, Kuruvilla S, Susruthan. Alveolar soft-part sarcoma of tongue. *Indian J Pathol Microbiol.* 2011; 54: 581-583.
54. **Conde N**, Cruz O, Albert A, Mora J. Antiangiogenic treatment as a pre-operative management of alveolar soft-part sarcoma. *Pediatr Blood Cancer* 2011; 57: 1071–1073.
55. **Rekhi B**, Ingle A, Agarwal M, *et al.* Alveolar soft part sarcoma ‘revisited’: clinicopathological review

- of 47 cases from a tertiary cancer referral centre, including immunohistochemical expression of TFE3 in 22 cases and 21 other tumours. *Pathology* 2012; 44:11-17.
56. **Argyris PP**, Reed RC, Manivel JC, *et al.* Oral alveolar soft part sarcoma in childhood and adolescence: report of two cases and review of literature. *Head and Neck Pathol* 2013; 7:40–9.
 57. **Kinger M**, Chakrabarti P, Varma A, Doshi B. Alveolar soft part sarcoma of tongue in 14-year-old boy. *Ann Maxillofac Surg* 2014; 4(2): 240–2.
 58. **Meng N**, Zhang X, Liao A, *et al.* Management of recurrent alveolar soft-part sarcoma of the tongue after external beam radiotherapy with iodine-125 seed brachytherapy. *Head Neck*. 2014; 36: E125–E128.
 59. **Liu H**, Hsiao Y, Chang C, *et al.* Alveolar soft part sarcoma of tongue- A rare case report. *Taiwan J Oral Maxillofac Surg*. 2014; 25: 269-275.
 60. **Wang H**, Qin X, Yang W, *et al.* Alveolar soft part sarcoma of the oral and maxillofacial region: clinical analysis in a series of 18 patients. *Oral Surg Oral Med Oral Pathol Oral Radiol*. 2015; 1-6. <http://dx.doi.org/10.1016/j.oooo.2014.12.013>.
 61. **Chopra N**, Tanveer N. An atypical presentation of alveolar soft part sarcoma of tongue. *J Lab Physicians* 2017; 9:220-221.
 62. **Yoshihiro T**, Tsuchihashi K, Nio K, *et al.* Lingual alveolar soft part sarcoma responsive to pazopanib. A case report. *Medicine*. 2017; 96:44(e8470) doi.org/10.1097/MD.00000000000008470.
 63. **Chatura KR**, Doradla S, Kusagur S. Alveolar soft part sarcoma in childhood: A report of two cases and review of literature. *J Adv Clin Res Insights*. 2017; 4: 16–20.
 64. **Katz AP**, Chen S, DeNardo BD, *et al.* Lingual alveolar soft part sarcoma in a pediatric patient: case report and literature review. *Int J Pediatr Otorhinolaryngol* 2017; 17:36-39.
 65. **Ruffle A**, Cameron M, Jonas N, *et al.* Lingual alveolar soft part sarcoma in a 1-year-old infant: youngest reported case with characteristic ASPSCR1-TFE3 fusion. *Pediatr Dev Pathol*. 2019; 1–5. DOI: 10.1177/1093526619830290.
 66. **Leszczynska M**, Jodeh DS, Reed D, *et al.* Alveolar soft-part sarcoma: case demonstrating principles for uncommon vascular lesions. *Pediatr Int*. 2019; 61: 978–981.
 67. **Hsu C**, Tseng C, Wang W. Alveolar soft part sarcoma of tongue in a 3-year-old Taiwanese. *J Dent Sci*. 2019; 14: 325-327.
 68. **Alegria-Landa V**, Lora V, Cota C, *et al.* Alveolar soft part sarcoma of the tongue. *Am J Dermatopathol* 2019; 41: 218-220.
 69. **Fouad A**, El Baz M, Mansouri N, *et al.* Lingual alveolar sarcoma in children: a rare soft tissue sarcoma. *Merit Res J Med Med Sci* 2019; 7: 1: 31-34.
 70. **Hornick JL**, editor. *Practical soft tissue pathology: a diagnostic approach*. Philadelphia, PA: Elsevier Saunders. 2013; p 178–180.
 71. **Gomez JA**, Amin MB, Ro JY, *et al.* Immunohistochemical profile of myogenin and MyoD1 does not support skeletal muscle lineage in alveolar soft part sarcoma. *Arch Pathol Lab Med* 1999; 123:503–507.
 72. **Argani P**, Lal P, Hutchinson B, *et al.* Aberrant nuclear immunoreactivity for TFE3 in neoplasms with TFE3 gene fusions: a sensitive and specific immunohistochemical assay. *Am J Surg Pathol* 2003; 27; 750-761.
 73. **Ladanyi M**, Lui MY, Antonescu CR, *et al.* The der(17)t(X;17)(p11;q25) of human alveolar soft part sarcoma fuses the TFE3 transcription factor gene to ASPL, a novel gene at 17q25. *Oncogene* 2001; 20; 48-57.
 74. **Joyama S**, Ueda T, Shimizu K, *et al.* Chromosome rearrangement at 17q25 and xp11.2 in alveolar soft-part sarcoma: a case report and review of the literature. *Cancer*. 1999; 86: 1246-1250.
 75. **Heimann P**, Devalck C, Debusscher C, *et al.* Alveolar soft part sarcoma: further evidence by FISH for the involvement of chromosome band 17q25. *Genes Chromosomes Canc*. 1998; 23: 194–197.