

NON-TRAUMATIC ECTOPIA LENTIS IN A PAEDIATRIC OPHTHALMOLOGY PRACTICE, IBADAN, NIGERIA

M.O Ugalahi¹, E.O Onebunne², B.A. Olusanya¹, A.M Baiyeroju¹

1. Department of Ophthalmology, University College Hospital/College of Medicine, University of Ibadan.
2. Department of Ophthalmology, University College Hospital Ibadan, Nigeria.

Correspondence:

Dr. E. Onebunne

Department of Ophthalmology,
University College Hospital,
Ibadan

Email: trashal23@yahoo.com

Submission Date: 5th June., 2023

Date of Acceptance: 30th Dec., 2023

Publication Date: 30th Jan., 2024

ABSTRACT

Background: Non-traumatic ectopia lentis is a rare ocular disorder usually associated with syndromes like Marfan's syndrome, Weil-Marchesani and Homocystinuria. Ectopia lentis can lead to profound visual loss from refractive errors, glaucoma as well as retinal detachment if left unattended.

Aim: The aim of this study was to describe the clinical profile of patients with non-traumatic ectopia lentis in a paediatric ophthalmology clinic in Ibadan, Nigeria.

Methods: The clinical records of children ≤ 16 years diagnosed with non-traumatic ectopia lentis at the Paediatric Ophthalmology Clinic, University College Hospital Ibadan, from May 1, 2015 to Dec 31, 2019 were retrospectively reviewed. Information on demography, family history, visual acuity (VA), mean refractive error (spherical equivalent), and management was retrieved.

Results: Clinical records of 25 patients were reviewed. The mean age was 8.9 (± 3.41) years with a range of 2-15 years. Sixteen (64%) patients were males. All the patients had bilateral involvement. A positive family history of ectopia lentis was elicited in 6 (24%) patients. Thirteen (52%) patients had a Marfanoid habitus and superior displacement of the lens was observed in 26 (52%) eyes. The presenting visual acuity was $< 6/60$ in 22 (44%) eyes. The spherical equivalent of the refractive errors ranged from -20.00DS to +13.25DS. Twenty (40%) eyes underwent surgery within the period of the study and the best corrected postoperative visual acuity improved by 2 or more lines in 12 (60%) of operated eyes.

Conclusion: Severe visual morbidity was common in this cohort of patients with ectopia lentis in our practice. Treatment provided some improvement in vision which highlights the need to encourage early presentation for care. Detailed family history is important as a few of the patients were diagnosed following acceptance of our invitation to siblings for ophthalmic evaluation.

Keywords: Ectopia lentis, Lensectomy, Aphakia, Childhood, Africa

INTRODUCTION

Ectopia Lentis is a hereditary or acquired displacement of the lens from its normal position.¹ In 1856, Karl Stellwag, an Austrian Ophthalmologist first introduced the term 'Ectopia Lentis' to describe an abnormal positioning of the crystalline lens relative to its natural position in the eye. Since then, it has been recognized as a hallmark of many systemic diseases; some of which have life threatening manifestations.² Hereditary ectopia lentis is frequently bilateral but rare case reports of familial unilateral ectopia lentis have been described.³ Congenital ectopia lentis is a rare ocular disorder. Point prevalence is reported as 0.83/10,000 live births in the Danish population.⁴ The prevalence in the Nigerian population is not known. However, a few cases have been reported in the country.⁵⁻¹¹ In Benin, a retrospective case series described the ocular features of both adults and children with Marfan's syndrome

in a hospital-based setting. The commoner ocular features in the cohort were ectopia lentis in 92.3%, cataract in 69.2%, glaucoma and myopia in 30.8% each.⁷ Severe visual impairment and blindness was found to occur from delayed presentation and use of traditional eye medication. In Lagos, a case report highlighted the importance of a family assessment in individuals suspected of having Marfan's syndrome. The report also underscored the need for detailed patient assessment in this syndrome that is associated with multiorgan involvement.⁶ A case report in Owo, southern Nigeria described bilateral ectopia lentis without any family history. Delayed presentation was a notable finding.⁸ Marfan's syndrome has also been reported in association with retinitis pigmentosa in a 24-year old man.¹⁰

Non-traumatic ectopia lentis, may occur in isolation but it is commonly associated with syndromes such as Marfan's syndrome, homocystinuria and Weill–Marchesani syndrome.¹² It is estimated that 1 in every 5000 individuals is affected by Marfan's syndrome.¹³ Non-syndromic cases may be sporadic or familial. Some syndromic associations of ectopia lentis may sometimes be life-threatening. Mitral valve prolapse, mitral regurgitation, aortic dilatation, aortic dissection, and aortic regurgitation are features that could be associated with significant cardiovascular mortality and morbidity.¹⁴ Therefore, a detailed systemic examination is pertinent for proper diagnosis, management, and prognostication. Some genetic mutations are known to be associated with specific phenotypic features hence correlating the phenotype with the genotype is useful in medical management algorithms.¹⁵ Genetic analysis could identify mutations that are not associated with extraocular manifestations hence refuting a need for extensive systemic investigations in the affected individuals.¹⁶ This makes genetic testing a very important tool in the management of ectopia lentis. Some common ocular features of ectopia lentis include mild to severe visual impairment, double vision, strabismus, and refractive errors. Other clinical features such as amblyopia, cataract, secondary glaucoma, and retinal detachment can markedly impair quality of vision with profound visual morbidity.¹³ Irrespective of the severity at initial presentation, the degree of the ectopia lentis and the disease progression with time vary among affected individuals.¹⁷

Management options include conservative measures using optical correction with spectacles or contact lenses, and surgical methods.^{12,18} Classical indications for surgical therapy include situations where the lens edge bisects the pupil, making it impossible to achieve a good optical correction; and an anteriorly displaced lens causing secondary glaucoma.¹⁷ Lensectomy is the most commonly performed surgical intervention and the approach (pars plana versus limbal) depends on the surgeon's expertise, as no study has shown a superiority of either approach.¹⁹

Visual rehabilitation following surgery can be challenging and may require multiple interventions and long term follow up. Options for visual rehabilitation include iris fixated intraocular lens (IOL), Scleral fixated IOL, as well as posterior chamber IOL insertion with the use of capsular tension rings (CTR).^{18–25} Contact lenses and aphakic spectacles are alternatives to IOLs but also have significant challenges.^{17,21} Aphakic spectacles are heavy, have accompanying prismatic distortion, constricted fields, scratch and may need frequent replacement while contact lenses could lead to neovascularization, may predispose to cornea

infection, and both could be associated with non-compliance.²⁶ Also, the cost of contact lenses may be prohibitive in our resource-constrained setting.

The possible sequelae of amblyopia, glaucoma and retinal detachment in children make early identification and prompt management vital for better outcomes.¹⁷ This is especially important in our environment where delayed presentation and financial constraints may adversely affect outcomes. Ectopia lentis although rare is a cause of avoidable blindness in the paediatric age group. Not much is known about the outcome of care in sub-Saharan Africa as only few case reports have been described in literature. Therefore, the aim of this study was to describe the clinical profile of a cohort of patients with non-traumatic ectopia lentis in a paediatric ophthalmology clinic in Ibadan, Nigeria with the aim of adding to the body of knowledge on this condition in sub-Saharan Africa.

METHODS

This study was a retrospective case series review of children aged 0 – 16 years who presented consecutively and were managed for non-traumatic ectopia lentis at the Paediatric Ophthalmology and Strabismus Clinic, University College Hospital (UCH), Ibadan, from May 1, 2015, to Dec 31, 2019. Ethical approval was obtained from the University of Ibadan/ UCH Ethical Review Committee, IRB number UC/EC/20/0302. Children, aged 16 years and below, diagnosed with ectopia lentis who presented to the clinic during the study period were included in the study. Patients with ectopia lentis due to trauma as an underlying cause for subluxation as well as those with missing records were excluded. Information on demography, family history of ectopia lentis, visual acuity (VA), mean refractive error (spherical equivalent), and management was retrieved from the medical records. Other information collected included age at the time of surgery, and postoperative refraction. A 2-line improvement in Snellen visual acuity following surgical management was considered a successful outcome. Patients were referred to the paediatrician for systemic evaluation which comprised physical examination and investigations. A cardiac evaluation with electrocardiography was done for all patients while some patients had echocardiography, in addition.

Lensectomy was performed using either an anterior segment approach or a pars plana approach. The anterior segment approach to lensectomy was performed by either of 2 paediatric ophthalmologists. The patient was placed under anesthesia, after which aseptic routine cleaning and draping was done. A scleral incision of 3 mm was made and tunneled into the clear cornea. A 2-3mm side port was created at the 9

o'clock position. Following anterior chamber entry, a high-molecular-weight viscoelastic material was injected into the anterior chamber, and anterior capsulorhexis was carried out. Aspiration of all lens matter from within the intact capsular bag was performed using a Simcoe canula. The vitrectomy probe was inserted into the anterior chamber and cutting mode was activated to remove the lens capsule, zonules, and the anterior vitreous making sure no vitreous extended to the wounds. On completion of the procedure, the wounds were closed with 10/0 nylon suture. Subconjunctival injection of antibiotic and steroid combination was given.

The pars plana approach to lensectomy performed by one consultant vitreoretinal surgeon. The patient was placed under anesthesia, after which aseptic routine cleaning and draping was done. Three 25-gauge trocars were inserted obliquely at the pars plana, 3.5 mm from the limbus. One trocar was placed in the inferotemporal quadrant for an infusion cannula while the other two were placed in the superonasal and superotemporal quadrants for the vitreous cutter and the light source, respectively. Lensectomy (ensuring complete capsular removal) and anterior vitrectomy were performed using the vitreous cutter. The trocars were removed, and the entry ports were examined to ensure they were self-sealing. Subconjunctival injection of antibiotic and steroid combination was given. Following lensectomy, patients were discharged from in-patient care after a week. Postoperative visits were scheduled at two weeks postoperatively, at four weeks, then monthly for three months, three monthly for a year and then six monthly thereafter. Patients left aphakic had refraction done and spectacles procured prior to discharge. The data was entered into an Excel® spreadsheet (Microsoft Corp., Redmond, WA, USA). Statistical Package for the Social Studies software (SPSS 20 IBM Corp., Armonk, NY, USA) w

summarized using frequencies and proportions for categorical data and measures of central tendency for numerical data.

RESULTS

Fifty eyes of 25 children met the inclusion criteria. There were 16 (64%) males and nine (36%) females. The age at presentation ranged from 2-15 years with a mean of 8.9 (± 3.41) years. Only eight (32%) of the patients presented before the age of 8 years. The details of the clinical profile of the patients are presented in Table 1. The presenting visual acuity (VA) ranged from 6/18 to No light perception (NLP) and was equal to or worse than 6/60 in 22 (44%) eyes. Objective visual acuity measurement was not available for three (12%) children. Refraction in 19 eyes showed high refractive errors with the spherical equivalent ranging from -20.00DS to +13.25DS. Glaucomatous cupping was present in both non-operated eyes of one (4%) patient and elevated intraocular pressure without disc cupping was found in both non-operated eyes of one (4%) patient. At presentation, there was superior displacement of the lens in 26 (52%) eyes, inferior displacement in 12 (24%), horizontal displacement with no vertical component in four (8%), while the direction of displacement was not documented in eight (16%) eyes. Lens opacities were seen in 12 (24%) eyes and three (6%) eyes had pre-existing retinal detachment at presentation.

Systemic examination revealed a Marfanoid habitus in 15 (60%) of the patients. There was cardiac pathology in four (16%) patients. The cardiac anomalies included aortic root dilatation (two patients), atrial septal defect (one patient) and cardiac arrhythmias (one patient). One patient (4%) had a diagnosis of Weill Marchesani syndrome, and one (4%) patient was diagnosed with Ectopia lentis et pupillae.

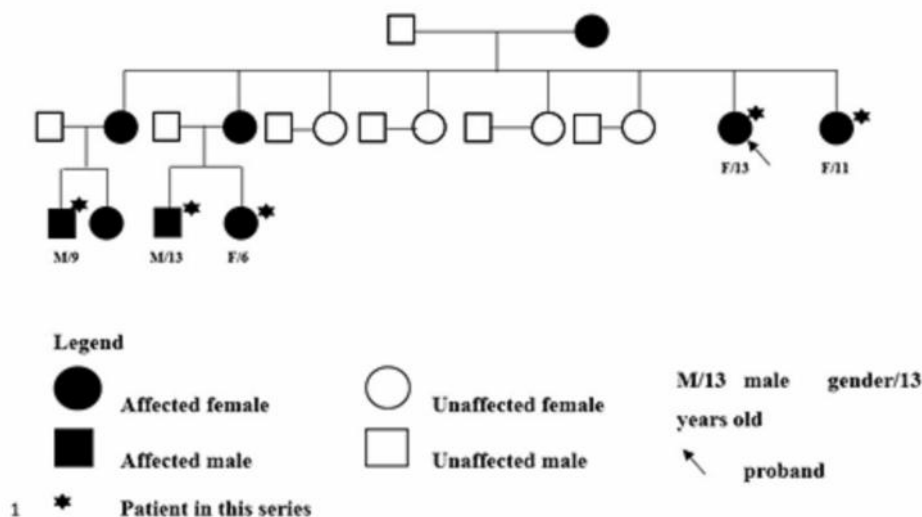


Figure 1: Pedigree charting of five patients in this series who belong to two generations of the same family

Table 1: Clinical profile of patients

SERIAL NUMBER/ SEX/AGE	PRESENTING VA*	BCVA / SE#	LENS SUBLUXATION	DIAGNOSIS	SURGERY	POST OP BCVA / SE
1/M/6	R CF L 6/24	R CF L 6/18 (-9.00)	R superior L superonasal	Marfanoid	R lensectomy + AV L lensectomy + AV	R CF L 6/9 (+13.50)
2/F/6	R 6/60 L 6/60	R 6/60 (+13.25) L 6/60	R superior L superior	Marfanoid	Nil	
3/M/7	R 6/60 L CF	R 6/60 (+8.00) L 3/60 (+7.50)	R Superonasal + cataract L Nasal	Marfanoid	Nil	
4/F/7	R CF L HM		R Superonasal + cataract L Inferotemporal + cataract		Defaulted	
5/M/9	R CF L 6/24	R 6/60 (+9.00) L 6/18 (+10.00)	R Superonasal + cataract L superonasal	Marfanoid	R lensectomy + AV L lensectomy + AV	R 6/12 (+9.75) L 6/12 (+9.50)
6/F/9	R 6/60 L 6/60	R 6/18 (-14.00) L 6/9 (-5.25)	R superotemporal L superotemporal		Nil	
7/M/9	R 6/60 L CF	R 6/36 (+11.00) L 6/36 (+11.00)	R superior L superotemporal + RD	Marfanoid	Nil	
8/M/9	R HM L 6/24	R HM L 6/12 (-5.50)	R Superonasal + cataract L superonasal		R SICS + PCIOL	
9/M/10	R CF L 6/60	L 6/60 (-20.00)	R Superonasal + cataract L superotemporal	Marfanoid	R lensectomy + AV L lensectomy + AV	R 6/24 (+8.50) L 6/24 (+10.75)
10/F/10	R 3/24 L 3/24		R inferonasal L inferonasal	Ectopia lentis et pupillae	Nil	
11/M/11	R NLP L HM		R phthisis L superotemporal + inferior RD	Marfanoid	nil	
12/F/13	R 6/60 L 6/36	R 6/60 L 6/36	R temporal L superotemporal + inferior RD	Marfanoid	R lensectomy + AV L lensectomy + AV	R 6/12 (+9.50) L 6/36 (+10.00)
13/M/15	R 6/36 L 6/36	R 6/12 (+11.00) L 6/18 (+7.00)	R inferotemporal L inferotemporal + cataract	Marfanoid	nil	
14/F/8	R 6/60 L 6/60	R 6/18 (-11.50) L 6/18 (-18.50)	nil		nil	
15/F/11				Marfanoid	L lensectomy + AV	R 6/18 (+9.00) L 6/18 (+10.50)
16/M/2	R CSM L CSM		R Inferior L inferior		bilateral pars plana vitrectomy + lensectomy	R CSM (+17.25) L CSM (+16.50)
17/M/5	R 3/60 L 3/60		R Inferotemporal, zonules intact L Inferotemporal, zonules intact	Marfanoid	R lensectomy + AV L lensectomy + AV,	R 6/12 (+3.25) L 6/18 (+3.25)
18/M/14	R 6/24 L NLP	R 6/24 L NLP	R superior, 270 zonular dialysis L superior + cataract + phthisis	Marfanoid	defaulted	
19/M/2	R CSM L CSM	R CSM L CSM	R superotemporal, zonules intact L superotemporal, zonules intact	Marfanoid	nil	
20/F/8	R HM L NLP		R microspherophakia + cataract in AC L Anterior staphyloma	Weill marchesani syndrome	R lensectomy + AV+ PI, L evisceration + implant	R 6/18 (+14.00)
21/M/13	R 6/18 L 6/24		R inferotemporal + cataract L inferotemporal + cataract		R lensectomy + AV R lensectomy + AV	RE LP, LE 6/9 (+6.50)
22/M/8	R CF L CF		R superior L inferotemporal		L Lensectomy + AV	
23/M/12	R HM L 6/24	R L 6/24 (-16.00)	R superonasal + cataract L coloboma + cataract		R Lensectomy + AV	R 6/60 (+6.50)
24/F/6	R CF L CF		R Superior L superior	Marfanoid	R lensectomy + AV	
25/M/13	R CF L CF	R 6/36 (-10.00) L 6/18 (-13.00)	R temporal L Nasal	Marfanoid	Nil	

*VA – Visual acuity

#BCVA / SE – Best corrected Visual acuity / Spherical equivalent

M – Male

F – Female

R – Right

Post op – post operative

L – Left

CF – Counting Fingers

HM – Hand Motions

NLP – Nil light perception

AV – Anterior vitrectomy

RD – Retinal detachment

SICS + PCIOL – Small Incision cataract surgery with posterior

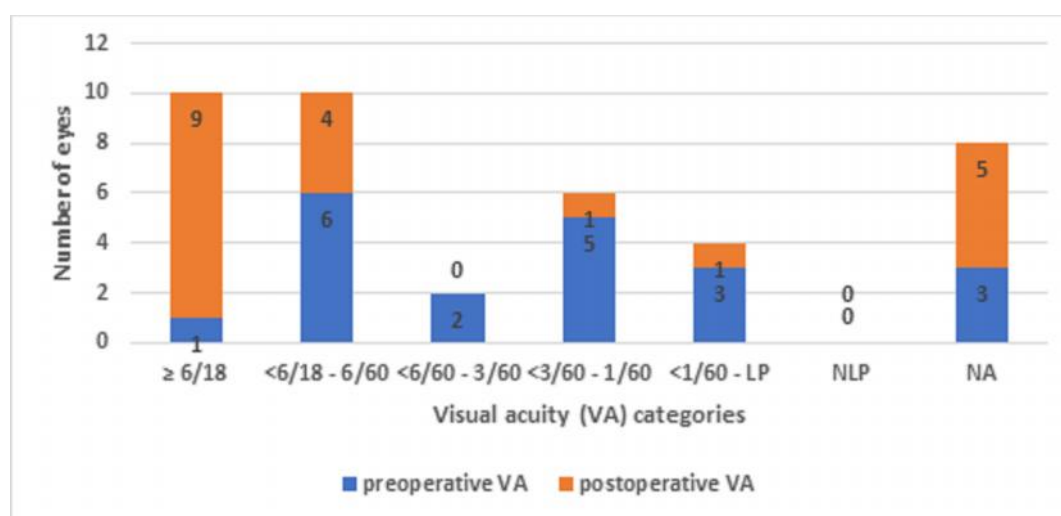
chamber intraocular lens

CSM – Central, Steady and

Maintained fixation

A family history of poor vision was elicited in 12(48%) patients and a diagnosis of ectopia lentis was confirmed in relatives of six (24%) patients. Figure 1 shows the pedigree chart of five patients in our series who belong to two generations of the same family. A 13-year-old female presented to the eye clinic with bilateral ectopia lentis and marfanoid habitus. Following successful surgery and visual rehabilitation with aphakic spectacles, her 11-year-old sister and three of their family members (a niece and two nephews) presented for care and were managed during the study period. The proband's mother also has ectopia lentis with marfanoid habitus and another sibling pair (proband's

improved by ≥ 2 lines in 12 (60%) eyes (Figure 2). Retinal detachment as a complication of lensectomy, was observed in two (10%) of the eyes operated in this series. One of these eyes underwent Scleral buckle surgery with initial visual outcome of 6/36. However, there was a re-detachment in the same eye after 19 months and final VA was HM. The other patient with postoperative retinal detachment was still awaiting surgery as at the time of this report due to financial constraints. Elevated intraocular pressure (IOP) was noted post-operatively in two (10%) eyes of two different patients and they were controlled on antiglaucoma medications.



NA- Visual acuity not assessed objectively

LP – Light perception

NLP – No light perception

VA – Visual acuity

Figure 2: Preoperative and postoperative visual acuity of 20 eyes that underwent surgery for ectopia lentis

niece and nephew) had had bilateral lensectomies in another eye hospital.

Twenty (40%) eyes of 13 patients underwent surgery within the study period. The mean age at surgery was 9.2 (± 3.76) years. There were 11 (55%) right eyes and nine (45%) left eyes. Lensectomy with anterior vitrectomy was performed in 19 (95%) eyes; via the limbal route in 16 (80%) eyes and via the pars plana route in three (15%) eyes. All 19 eyes were left aphakic. One (5%) eye had small incision cataract surgery (SICS) with insertion of a posterior chamber intraocular lens (PCIOL). This eye had zonular dialysis limited to only one quadrant.

The preoperative presenting VA ranged from 6/18 to Hand Motion (HM) and only one (5%) eye had a VA of 6/18. The best corrected postoperative visual acuity was $\geq 6/18$ in nine (45%) of the operated eyes. Vision

DISCUSSION

This is, perhaps, the largest series of non-traumatic ectopia lentis reported thus far in African children. At presentation, the age range in the current study was 2-15 years with a mean age of 8.9 years which was similar to that reported by Shafique *et al.*²⁷ (range of 5-12 years) and Noorani *et al.*²⁸ (mean 9.4 years, range 2.5 – 15 years), both in Pakistan. The age of the youngest child in our cohort is in keeping with previous reports that non-traumatic ectopia lentis can manifest at a very young age. A study in China found that more than 50% of patients with Marfan's syndrome developed ectopia lentis before 5 years of age or during early childhood.¹⁵ In this present series, the mean age at surgery was 9.2 years. Other studies have reported younger age at surgery including Anteby *et al.*²³ in Israel (mean age 6.4 years), Hsu *et al.*¹⁹ in the USA (mean age 5.86 years), Konradsen *et al.*¹⁸ in Sweden (median age 4.3 years) and Dureau *et al.*²⁰ in France (median age

4.8years). The study by Ukponmwan⁷ in Benin had an older cohort with age range from 10-50 years and a mean age of 23years. Even though the youngest child in our cohort was 2 years, most patients in our series were much older at presentation. Late presentation appears to be common in our environment.^{7,8} Financial constraints were responsible for the late presentation in a local study.⁸ The late presentation may account for the disparity between the age at surgery in our study and previous studies. In addition, late presentation has significant implications for the development of amblyopia.

The best corrected visual acuity (BCVA) at presentation was $>6/18$ in only 18% of all our patients. In our patients who had surgery, the preoperative BCVA was $\leq 6/18$ in all eyes where an objective VA assessment could be obtained. The visual impairment in these patients, we believe, is due to a combination of uncorrected high refractive errors and amblyopia. This range of visual impairment in the present study is similar to reports by Hsu *et al.*¹⁹ in USA (worse than or equal to 6/18), Dureau *et al.*²⁰ (worse than or equal to 6/15), Wu-Chen *et al.*²⁹ in USA (worse than or equal to 6/18), Anteby *et al.*²³ in Israel, and Noorani *et al.*²⁸ in Pakistan (worse than or equal to 6/30).

More than half of the eyes in our series had superior displacement of the lens. This is contrary to findings by Shafique *et al.*²⁷ who reported 75% inferior subluxation. This could be explained by the fact that more patients in our series had features suggestive of Marfan syndrome in contrast to homocystinuria reported in their study. The direction of lens dislocation is most commonly superior or superotemporal in Marfan's syndrome even though the lens could be dislocated in any direction including inferiorly.³⁰ Lens dislocation in homocystinuria commonly occurs in the inferior direction.²

A significant proportion of our patients had high refractive errors at presentation. This is similar to the high myopic astigmatism reported by Hsu *et al.*¹⁹ Also, lens opacities were seen in 12 (24%) eyes of our patients, which is quite similar to the 20% reported by both Shafique *et al.*²⁷ and Noorani *et al.*²⁸ A combination of these, in addition to the older age at presentation and the extent of lens subluxation with respect to the visual axis increased the risk of amblyopia and possibly affected the visual outcome in our patients.

The pedigree chart of five related patients in our cohort who belong to two generations of the same family highlights the need for a detailed family history and examination of all family members. The proband had

been enrolled in the school for the blind due to poor vision and was referred to our clinic from the school. Following satisfactory visual improvement with surgery and aphakic spectacles, her sister, mother, nephews, and niece also presented to the eye clinic for treatment. All these relatives except her mother are among the patients in this case series. In the entire study cohort, a family history of poor vision was elicited in 48% of our probands however a diagnosis of ectopia lentis was confirmed in relatives of 24% patients as most relatives could not present to a clinic for physical examination. A 46.2% positive family history of ocular and phenotypic features associated with Marfan's syndrome has been reported in parents and siblings of probands in a Nigerian case series.⁷ Similarly, Noorani²⁸ reported that a third of their patients had familial ectopia lentis.

Management of patients with ectopia lentis should be comprehensive with respect to diagnosis, detection of systemic comorbidities, counselling and examination of at-risk relatives, indication and timing of surgery, surgical approach, visual rehabilitation and need for long-term follow up. In view of the progressive nature of the disease and the variable severity among patients, it is challenging to establish an absolute standard of care. There are still controversies as to the adequacy of conservative management.¹⁷ Lack of improvement in vision with conservative approach is the commonest indication for surgery.²¹

For the patients who had surgical management in our series, lensectomy with anterior vitrectomy was performed in 95% of the eyes and the limbal route was used in majority of the eyes. This was largely due to surgeons' preference and lack of facilities for posterior vitrectomy in our center which is the scenario in most resource-poor settings.³¹ These eyes were all left aphakic. In the study by Ukponmwan,⁷ all 5 patients who had cataract extraction received IOL implants.

Postoperatively, the best corrected visual acuity was $\geq 6/18$ in only about half of the eyes in our series. The high proportion of patients with suboptimal vision/visual impairment despite best correction could be attributed to amblyopia as a significant proportion had high ametropia and/or presented late for care. Even in the absence of any of these, ectopia lentis in a child is a known risk factor for amblyopia.^{2,29} Furthermore, the sub-optimal optical correction of surgical aphakia with aphakic spectacles could be contributory.

Noorani *et al.*²⁸ in their large cohort of 54 surgical eyes also corrected surgical aphakia using aphakic spectacles and contact lenses but noted significant visual improvement with 71% achieving $\geq 6/18$. They

attributed the poor postoperative vision of 6/60 - HM to preoperative glaucoma present in half of their patients and irreversible amblyopia in about a third.²⁸ Other identifiable factors responsible for the poorer BCVA include older age at surgery, short follow up duration, mild visual axis opacification, and residual refractive errors.¹⁸ Comparing their study to ours, they had 6 (11%) patients below 5 years in the surgery arm and 31(57%) between 5-10 years in the surgery arm, altogether 68% of their study cohort <10 years of age. Meanwhile only 10(40%) of our patients in the present study were 10 years or below at time of presentation. Amblyopia was expected to be more common in our study group affecting BCVA considering majority presented after the age of 8 years when visual development is already established, hence the difference in visual outcome post-surgery and optical rehabilitation is not surprising.

On the other hand, better visual outcomes have been recorded in some studies.^{12,29,32} Even though 78% of their patients were >5years at the time of surgery and there was no IOL implantation, Halpert and BenEzra¹² were able to achieve VA $\geq 20/40$ (6/12) in 80% (47) of eyes. Anteby *et al.*²³ recorded postoperative VA $\geq 20/40$ (6/12) in 84.2% with a mean age of 6.4 years and no IOL insertion. Wu-Chen *et al.*²⁹ also recorded VA improvement in all cases and BCVA was $\geq 20/30$ (6/9) in 82.4% despite a mean age of 7.7 years and no IOL insertion. The reasons for the differences in visual outcomes are unclear.

Furthermore, Anteby *et al.*²³ found an interesting behavior of the BCVA after long follow-up duration. They noted that the average time for the first operated eye to reach BCVA was 7.0 months (range, 1.5 months–2.0 years). However, a shorter duration of follow up of one-year, Nb *et al.*³² documented BCVA of $\geq 20/30$ in 84% postoperatively. This may be attributed to use of intraocular lenses in their cohort which allows for better visual rehabilitation.

Postoperative retinal detachment observed in this series is not uncommon and has been reported in other studies.^{12,28} Retinal detachment was reported up to 2 years post lensectomy with improved visual acuity post repair by Halpert and BenEzra in Israel.¹² Postoperative elevated IOP was also noted in two eyes in our study. Even with a mean follow-up of 4.6years Halpert and BenEzra¹² recorded normal IOP in the range of 12-18mmHg throughout the follow up period in all their patients. Other reported postoperative complications of aphakia following lensectomy for ectopia lentis management include transient ocular hypertension, transient vitreous hemorrhage, wound dehiscence, iris incarceration, iridocorneal adhesions, vitreous

haemorrhage, and glaucoma secondary to pupillary block.^{23,29} Long-term follow-up is required to monitor for complications such as glaucoma and retinal detachment in children with ectopia lentis.

Insights gained from this study could influence clinical decision-making and potentially lead to improved patient outcomes. Our findings suggest a need for potential public health interventions to encourage early diagnosis and access to timely care as early identification and treatment may improve visual outcome and general wellbeing of affected children. Also, screening of children at birth, at school entry and school eye health programs could identify children with visual problems which are treatable. Additionally, our findings might inform treatment guidelines in resource-poor settings. One application could be specifically targeting children born to parents with visual impairment to have scheduled visual evaluation to detect familial visual conditions like ectopia lentis amongst others. Also, incorporation of genetic counselling during antenatal care will create more awareness among people at risk of having children with ectopia lentis. This may encourage early detection and care of affected offspring.

There are also suggested directions for future research such as genetic studies in patients with rare ocular disorders.

There are some limitations to our study. Molecular diagnostic facilities are not available in our centre, the diagnosis of Marfan syndrome in our series was therefore purely clinical and was made in about half of the patients. It was based on the presence of ectopia lentis (a major diagnostic criterion), and other suggestive clinical features such as marfanoid habitus and cardiac anomalies. The retrospective nature of the study made data retrieval a challenge with some missing data. Furthermore, some patients were lost to follow-up. Like all hospital-based studies, the findings are not generalizable to the general population due to referral bias, however non traumatic ectopia lentis is a rare condition and affected individuals would eventually seek care in hospitals as a result of profound visual loss.

CONCLUSION

Ectopia lentis, though rare, causes profound visual morbidity. Management of ectopia lentis in a tertiary eye hospital in Nigeria provides some improvement in vision and patients should be encouraged to access care early. Detailed systemic examination and family history are important and should be routinely evaluated. The complications of our surgical approach were few, and most of such complications could be

managed medically and surgically. There is a need for public health interventions to encourage early diagnosis and uptake of care.

Declarations

Funding: None to declare. This research did not receive any specific grant from funding agencies in the public, commercial or not-for-profit sectors

Conflicts of interest/Competing interests: None to declare

Ethics approval: obtained from the University of Ibadan/ UCH Ethical Review Committee. 20/0302

ACKNOWLEDGEMENT

MOU and BAO are supported by Consortium for Advanced Research Training in Africa (CARTA) which is funded by the Carnegie Corporation of New York (Grant No—B 8606.R02), Sida (Grant No:54100029), the DELTAS Africa Initiative (Grant No: 107768/Z/15/Z)

REFERENCES

1. **Bowling B.** Kanski's Clinical Ophthalmology. 8th ed. Edinburgh: Elsevier; 2016. 307–347.
2. **Neely DE,** Plager DA. Management of Ectopia Lentis in Children. *Ophthalmol Clin North Am.* 2001;14(3):493–499.
3. **Simon JW,** Cotliar JM, Burke LW. Familial unilateral ectopia lentis. *J AAPOS.* 2007;11:620–621.
4. **Fuchs J,** Rosenberg T. Congenital ectopia lentis. A Danish national survey. *Acta Ophthalmol Scand.* 1998;76(1):20–26.
5. **Magulike N,** Aghaji AE. Weill-Marchesani syndrome in Nigeria: Report of a case that presented with bilateral cataract. *Niger J Ophthalmol.* 2004;12(1):23–25.
6. **Ekure E,** Onakoya A, Oke D. Marfan's syndrome: a study of a Nigerian Family and review of current cardiovascular management. *West Afr J Med.* 2009;28(1):48–53.
7. **Ukponmwan C.** Ocular features and management challenges of Marfan's Syndrome in Benin City, Nigeria. *Niger Postgr Med J.* 2013;20(1):24–28.
8. **Omolase C,** Akinwalere A, Omotayo R, *et al.* Bilateral Ectopia Lentis in Marfan's syndrome: a case Report. *Clin Surg.* 2018; 3:2244.
9. **Nwokocha A,** Arodiwe I, Adiele K, *et al.* Marfan Syndrome: A case report. *Afr J Med Heal Sci.* 2016;15:107–109.
10. **Abba Kaka HY.** Retinal Degenerative Disease (Retinitis Pigmentosa) Associated with Nonocular Abnormalities: A Case Series in Niger. *Niger J Ophthalmol [Internet].* 2023;31(1). Available from: https://journals.lww.com/njoo/fulltext/2023/31010/retinal_degenerative_disease__retinitis.7.aspx
11. **Oguntola BO,** Adebayo RA, Akinyele OA, Adeyinka D. Marfan Syndrome: an uncommon cause of heart failure with late presentation and management challenges in a Nigerian patient (case report). *PAMJ Clin Med.* 2023;11(2).
12. **Halpert M,** BenEzra D. Surgery of the hereditary subluxated lens in children. *Ophthalmology.* 1996; 103(4):681–686.
13. **Ho NC,** Tran JR, Bektas A. Marfan's syndrome. *Lancet.* 2005;366(9501):1978–1981.
14. **van Karnebeek CD,** Naeff MS, Mulder BJ, *et al.* Natural history of cardiovascular manifestations in Marfan syndrome. *Arch Dis Child.* 2001; 84 (2):129–137.
15. **Li J,** Jia X, Li S, *et al.* Mutation survey of candidate genes in 40 Chinese patients with congenital ectopia lentis. *Mol Vis.* 2014;20 (2):1017–1024.
16. **Musleh M,** Bull A, Linton E, *et al.* The Role of Genetic Testing in Children Requiring Surgery for Ectopia Lentis. *Genes (Basel).* 2023 Mar;14(4).
17. **Matsuo T.** How far is observation allowed in patients with ectopia lentis/? Springerplus. 2015; 4:461.
18. **Konradsen T,** Kugelberg M, Zetterstrom C. Visual outcomes and complications in surgery for ectopia lentis in children. *J Cataract Refract Surg.* 2007;33:819–824.
19. **Hsu HY,** Edelstein SL, Lind J'T. Surgical management of non-traumatic pediatric ectopia lentis/: A case series and review of the literature. *Saudi J Ophthalmol.* 2012;26(3):315–321.
20. **Dureau P,** Meux PDL De, Edelson C, Caputo G. Iris fixation of foldable intraocular lenses for ectopia lentis in children. *J Cataract Refract Surg.* 2006;32(July):1109–1114.
21. **Simon MA,** Origlieri CA, Dinallo AM, *et al.* New Management Strategies for Ectopia Lentis. *J Pediatr Ophthalmol Strabismus.* 2015;52(5):269–281.
22. **Kopel AC,** Carvounis PE, Hamill MB, *et al.* Iris-sutured intraocular lenses for ectopia lentis in children. *J Cataract Refract Surg.* 2008 Apr; 34(4): 596–600.
23. **Anteby I,** Isaac M, BenEzra D. Hereditary subluxated lenses: Visual performances and long-term follow-up after surgery. *Ophthalmology.* 2003;110(7):1344–1138.
24. **Català-Mora J,** Cuadras D, Díaz-Cascajosa J, *et al.* Anterior iris-claw intraocular lens implantation for the management of nontraumatic ectopia lentis: long-term outcomes in a paediatric cohort. *Acta Ophthalmol.* 2017 Mar;95(2):170–174.
25. **Cai L,** Han X, Jiang Y, *et al.* Three-Year Outcomes of Cionni-Modified Capsular Tension Ring

- Implantation in Children Under 8 Years Old With Ectopia Lentis. *Am J Ophthalmol.* 2021 Apr; 224: 74–83.
26. **Baradaran-Raffi A**, Shirzadeh E, Eslani M, Akbari M. Optical correction of aphakia in children. *J Ophthalmic Vis Res.* 2014 Jan;9(1):71–82.
 27. **Shafique M**, Muzaffar W, Ishaq M. The eye as a window to a rare disease: ectopia lentis and homocystinuria, a Pakistani perspective. *Int Ophthalmol.* 2016;36(1):79–83.
 28. **Noorani S**, Khan A, Rubab S, Choudhary KA. Management of Ectopia Lentis in Children. *Pak J Ophthalmol.* 2007;23(4):181–187.
 29. **Wu-chen WY**, Letson RD, Summers CG. Functional and Structural Outcomes Following Lensectomy For Ectopia Lentis. *J AAPOS.* 2005; 9:353–357.
 30. **Banerjee PJ**, Chandra A. Ectopia lentis: systemic associations and direction of displacement. *Int Ophthalmol.* 2013;33(3):217–218.
 31. **Sunday OT**. Should Posterior Vitrectomy be Made a Priority in Ophthalmic Facilities of Sub Sahara Africa? *Open Ophthalmol J.* 2013;7:1–3.
 32. **Nb K**, Kohli P, Pratap B, *et al.* Evaluation of Sutureless, Glueless, Flapless, Intracocular fixated Posterior Chamber Intraocular Lens in Children with Ectopia Lentis. *J Ophthalmol.* 2018;2018